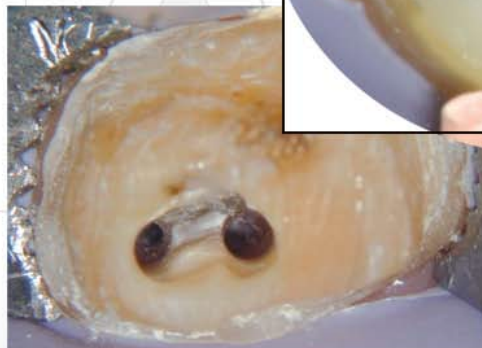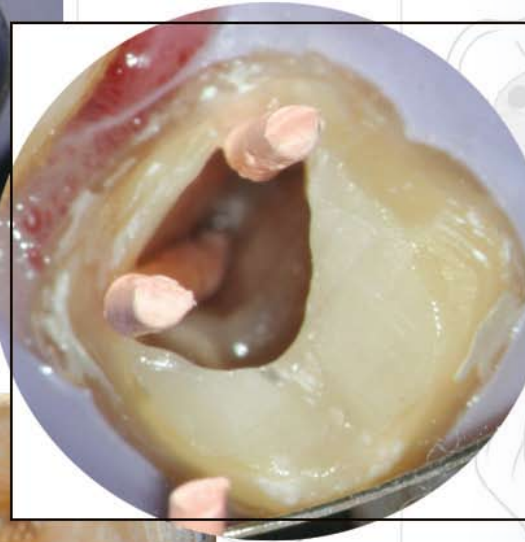
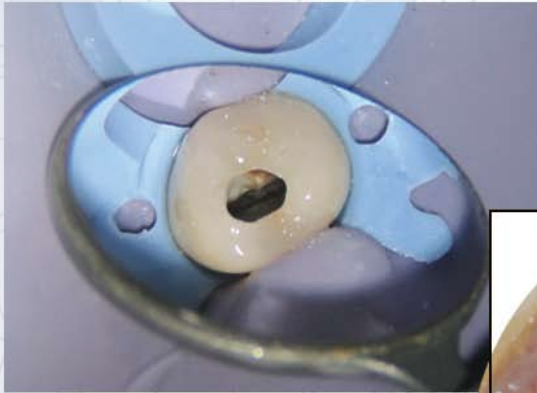


Earn

4 CE credits

This course was written for dentists, dental hygienists, and assistants.



Guidelines for Access Cavity Preparation in Endodontics

A Peer-Reviewed Publication

Written by Ricardo Caicedo; Dr. Odon; Stephen Clark, DMD; Lilia Rozo, DDS and Joseph Fullmer, BA

ADA CERP

Continuing Education
Recognition Program

PennWell is an ADA CERP recognized provider

ADA CERP is a service of the American Dental Association to assist dental professionals in identifying quality providers of continuing dental education. ADA CERP does not approve or endorse individual courses or instructors, nor does it imply acceptance of credit hours by boards of dentistry.

Concerns of complaints about a CE provider may be directed to the provider or to ADA CERP at www.ada.org/goto/cerp.

PennWell®

dental
CE
digital

inneedce.com
The Academy of Dental
Therapeutics and Stomatology™

Go Green, Go Online to take your course

This course has been made possible through an unrestricted educational grant. The cost of this CE course is \$59.00 for 4 CE credits.

Cancellation/Refund Policy: Any participant who is not 100% satisfied with this course can request a full refund by contacting PennWell in writing.

Educational Objectives

Upon completion of this course, the clinician will be able to do the following:

1. Understand access as the most important phase of nonsurgical root canal treatment
2. Comprehend principles of cavity preparation and proposed guidelines to accurately prepare and fill the radicular pulp space
3. Understand the four parts to endodontic coronal cavity preparation—outline form, convenience form, removal of remaining carious dentin and defective restorations, and cleansing of the cavity
4. Understand the differences in chamber and access shape for each tooth type and protocol to follow when performing on each

Abstract

Adequate access is essential for successful endodontic treatment. Knowledge of pulp chamber morphology, along with an examination of preoperative radiographs, should be integrated when designing the access cavity to a tooth for nonsurgical root canal treatment. Once the coronal cavity has been adequately prepared, including the removal of carious dentin and defective restorations, a variety of instruments can be used in the process itself. Great variance in overall tooth size, morphology, and arch position means that no two access openings are identical, although common access guidelines have been established depending on the location of the tooth. This article is a review of the endodontic access and anatomic landmarks relating to the pulp chamber.

Access is the most important phase of nonsurgical root canal treatment. A well-designed access preparation is essential for an optimum endodontic result. Without adequate access, instruments and materials become difficult to handle properly in the highly complex and variable root canal system. The objectives of access cavity preparation consist of the following:

1. To achieve straight-line access to the apical foramen or to the initial curvature of the canal
2. To locate all root canal orifices
3. To conserve sound tooth structure

The ideal access cavity creates a smooth, straight-line path to the canal system and ultimately to the apex. When prepared correctly, the access cavity allows complete irrigation, shaping, cleaning, and quality obturation. Optimal access results in straight entry into the canal orifice, with the line angles forming a funnel that drops smoothly into the canal(s). Projection of the canal center line to the occlusal surface of the tooth indicates the location of the cavosurface line angles. Connection of the line angles creates the outline form.

Green V. Black's principles of cavity preparation, including outline, convenience, retention, and resistance forms, should be applied while thinking of an endodontic preparation as a continuum from enamel surface to apex (Figure 1). The entire length of the preparation is the full outline form. Sometimes, this outline may have to be modified for the convenience of a canal anatomy, radicular dilacerations, or insertion of endodontic instruments.¹

In a study involving 500 pulp chambers, Krasner and Rankow² found that the cementoenamel junction (CEJ) was the most important anatomic landmark for determining the location of pulp chambers and root canal orifices. The

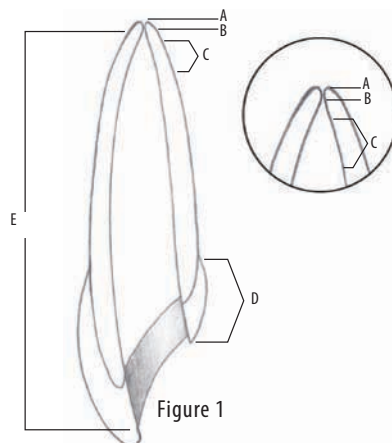


Figure 1

study demonstrated the existence of a specific and consistent anatomy of the pulp chamber floor. These authors proposed five guidelines, or laws, of pulp chamber anatomy to help clinicians determine the number and location of orifices on the chamber floor. In order to accurately prepare and properly fill the radicular pulp space, intracoronary preparation must be correct in size, shape, and inclination. Deutsch and Musikan³ studied the morphology of the chamber and found that the ceiling of the pulp chamber was at the level of the cemento-enamel junction in 97 percent to 98 percent of the maxillary and mandibular molars. These findings should be integrated during the endodontic access preparation.

Developments in electric hand-piece engineering allow one motor to provide both low- and high-speed utility. For initial entrance of the coronal cavity preparation through the enamel surface or through a restoration, the ideal cutting instrument is a round-end carbide fissure bur.⁴ With this instrument, enamel, resin, ceramic, or metal perforation is easily accomplished, and surface extensions may be rapidly completed (Figure 2). Manufactured models of this instrument include Maillefer Endo Z bur (Dentsply/Maillefer, Tulsa, Okla.), LA Axxess Diamond (Sybron-Endo), Brasseler H269GK, Axis Dental H269GK-FG, and Meisinger HM23R. For the clinician to master the anatomic concept of cavity prepa-

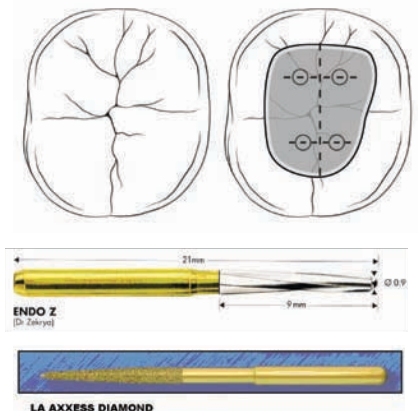


Figure 2

ration, he must develop a mental three-dimensional image of the interior of the tooth, from the pulp horn to the apical foramen (Figure 3). Unfortunately, conventional radiographs provide only a two-dimensional image of pulp anatomy. It is the third dimension that the clinician must mentally visualize, as a supplement to two-dimensional thinking, if one is to accurately clean, shape, obturate, and fill the total pulp space (Figure 4). The anatomy of the canals dictates modifications of the cavity preparation. If, for example, a fourth canal is found or suspected in a molar tooth, the preparation outline will have to be expanded to allow for easy access into the accessory canal. Endodontic preparations deal with both coronal and radicular access, each of which is achieved separately but ultimately flow together into a single preparation.

Endodontic Coronal Cavity Preparation⁵

I. Outline Form

II. Convenience Form

III. Removal of the Remaining Carious Dentin and Defective Restorations

IV. Cleansing of the Cavity

I. Outline Form

The outline form of the endodontic cavity must be correctly shaped and positioned to establish complete access for instrumentation, from cavosurface margin to apical foramen.

II. Convenience Form

Convenience form, as conceived by Black, is a modification of the cavity outline form to establish greater convenience in the placement of intra-coronal restorations.¹ In endodontic therapy, however, this form provides more convenient and accurate preparation and filling of the root canal. Four important benefits are gained through convenience form modifications:

1. Unobstructed access to the canal orifice,
2. Direct access to the apical foramen,

3. Cavity expansion to accommodate filling techniques, and
4. Complete authority over the enlarging instrument (Figure 5).⁶

III. Removal of the Remaining Carious Dentin and Defective Restorations

Caries and defective restorations remaining in an endodontic cavity preparation must be removed for three reasons:

1. To mechanically eliminate as many bacteria as possible from the interior of the tooth
2. To eliminate the discolored tooth structure that may ultimately lead to staining of the crown
3. To reduce the risk of bacterial contamination of the prepared cavity

IV. Cleansing of the Cavity

All of the caries, debris, and necrotic material must be removed from the chamber before the radicular instrumentation is begun. This should be done without the use of an air syringe due to the possibility of an air embolism. Sodium hypochlorite (NaOCl) should also be used during the access preparation for its added benefits of disinfection, removal of hemorrhagic or purulent fluids, and flushing action of debris and dentin chips.

Common Access⁷

Maxillary Central Incisors

The morphology of the chamber is triangular in design with high pulp horns on mesial and distal aspects of the chamber. The access opening is triangular in shape. The outline form of the access cavity changes to a more oval shape as the tooth matures and the pulp horns recede because the mesial and distal pulp horns are less prominent. A lingual ledge or lingual bulge is often present (Figure A).

Maxillary Lateral Incisors

The chamber is similar to central incisors but proportionately smaller.

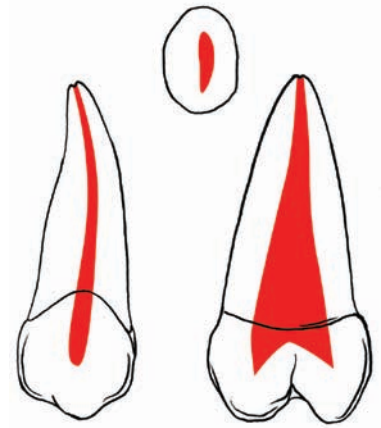


Figure 3

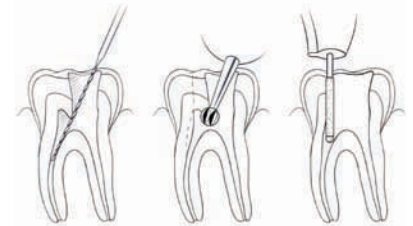


Figure 4

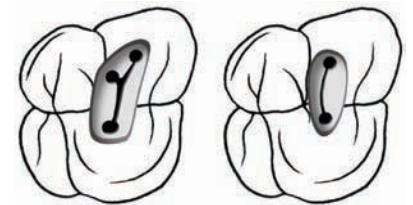


Figure 5

The access opening is triangular, similar to maxillary central incisors, and proportionately smaller in the middle third of the lingual surface of the tooth. A lingual ledge may also be present but is usually not clinically significant. If a lingual shoulder of dentin is present, it must be removed before instruments can be used to explore the canal (Figure B).

Maxillary Canine

The chamber shape is usually elliptical or oval. The access opening is oval on the lingual surface and should be in the middle third of the tooth, both mesio-distally and incisal-apically. Because of its shape, the clinician must take care to circumferentially file the access opening labially and palatally to shape and clean the canal properly. A lingual

ledge may be present but is usually not clinically significant (Figure C).

Maxillary First Premolar

The chamber is usually oval and maintains a similar width from the occlusal level to the floor, which is located just apical to the cervical line. The palatal orifice is slightly larger than the buccal orifice. In cross section at the CEJ, the palatal orifice is wider buccolingually and kidney-shaped because of its mesial concavity. The access opening is oval on the occlusal surface and should be in the middle third of the tooth, both mesiodistally and buccolingually. Buccal and lingual cusps should not be undermined during access opening preparation. The buccal pulp horn usually is larger. There are often ledges of calcification on the buccal and/or lingual walls just coronal to the orifice that may inhibit straight-line access to the canal system (Figure D).

Maxillary Second Premolar

The chamber morphology is usually oval. A buccal and a palatal pulp horn are present; the buccal pulp horn is larger. The access opening is oval on the occlusal surface and should be in the middle third of the tooth, both mesiodistally and buccolingually. The buccal and lingual cusps should not be undermined during access opening preparation. The single root is oval and wider buccolingually than mesiodistally, so the canal(s) remains oval from the pulp chamber floor and tapers rapidly to the apex (Figure E).

Maxillary First Molar

The chamber is usually triangular or square, and the access opening is triangular to slightly square on the occlusal surface. Preparation of the access should be distal to the mesial

marginal ridge, within the middle one-third buccolingually, and mesial to the transverse ridge. Care should be taken not to undermine the transverse ridge during preparation or to extend the access opening so far mesially as to undermine the mesial marginal ridge. The palatal canal orifice is centered palatally, the distobuccal orifice is near the obtuse angle of the pulp chamber floor, and the main mesiobuccal canal orifice (MB-1) is buccal and mesial to the distobuccal orifice positioned within the acute angle of the pulp chamber. The second mesiobuccal canal orifice (MB-2) is located palatal and mesial to the MB-1. A line drawn to connect the three main canal orifices—MB orifice, distobuccal (DB) orifice, and palatal (P) orifice—forms a triangle known as the molar triangle (Figure F).

Maxillary Second Molar

This shape of this chamber is usually less triangular and more oval than the maxillary first molar. The access opening is triangular, but becomes more straightened in a mesiobuccal-palatal direction. Preparation of the access should be distal to the mesial marginal ridge, within the middle one-third buccolingually, and mesial to the transverse ridge. Care should be taken not to undermine the transverse ridge during preparation. The opening begins slightly more distally than in the first molar because of the location of the canal and root structure. When four canals are present, the access cavity preparation of the maxillary second molar has a rhomboid shape and is a smaller version of the access cavity for the maxillary first molar. If only three canals are present, the access cavity is a rounded triangle with the base to the buccal. As with the maxillary first molar, the mesial marginal ridge need not

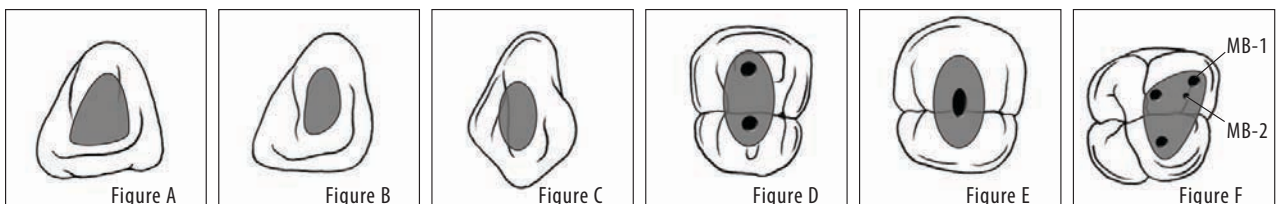
be invaded. Because the tendency in maxillary second molars is for the distobuccal orifice to move closer to a line connecting the MB and P orifices, the triangle becomes more obtuse and the oblique ridge is normally not invaded. If only two canals are present, the access outline form is oval and widest in the buccolingual dimension. Its width corresponds to the mesiodistal width of the pulp chamber, and the oval usually is centered between the mesial pit and the mesial edge of the oblique ridge (Figure G).

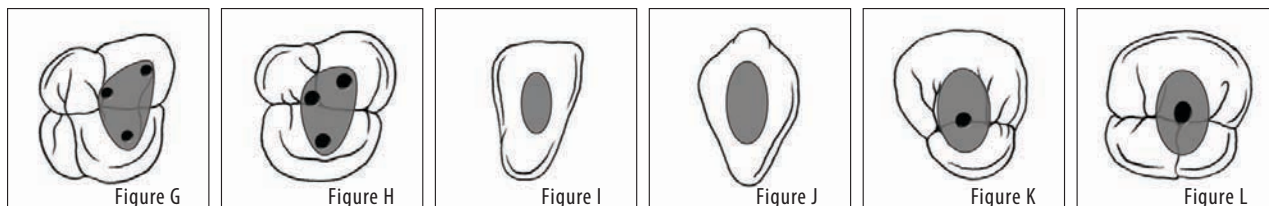
Maxillary Third Molar

The chamber is usually less triangular and more oval in shape than the maxillary second molar. The access opening is somewhat triangular, but tends to rotate as the DB canal orifice becomes more aligned with the palatal canal. Preparation can begin in the central fossae and proceed in a buccopalatal direction. The access cavity form for the third molar can vary greatly, because the tooth typically has one to three canals that would require the access preparation to be anything from an oval that is widest in the buccolingual dimension to a rounded triangle similar to that used for the maxillary second molar. The MB, DB, and P orifices often lie nearly in a straight line. The resultant access cavity is an oval or a very obtuse triangle (Figure H).

Mandibular Central and Lateral Incisors

The chamber shape is triangular to oval in design, with high pulp horns on mesial and distal aspects of the chamber in younger patients. A lingual ledge or lingual bulge may be present, which restricts visualization of the canal orifice and prevents straight-line access of the canal system. Often, the access open-





ing must be extended more lingually in order to obtain straight-line access to the lingual orifice and the canal system. In addition, all working length films taken of mandibular incisors should be exposed at a slight mesial or distal angle to confirm the presence or absence of a second canal. Due to their small size and internal anatomy, the mandibular incisors may be the most difficult access cavities to prepare. The external outline form may be triangular or oval, depending on the prominence of the mesial and distal pulp horns. When the form is triangular, the incisal base is short and the mesial and distal legs are long incisogingivally, creating a long, compressed triangle. Without prominent mesial and distal pulp horns, the oval external outline form also is narrow mesiodistally and long incisogingivally. Complete removal of the lingual shoulder is critical, because this tooth often has two canals that are buccolingually oriented, and the lingual canal is most often missed. To avoid this, the clinician should extend the access preparation well into the cingulum gingivally. Because the lingual surface of this tooth is not involved with occlusal function, butt joint junctions between the internal walls and the lingual surface are not required (Figure I).

Mandibular Canine

The morphology of the chamber is usually elliptical or oval, and a lingual ledge may be present. The access opening is oval on the lingual surface and should be in the middle one-third of the tooth, both mesiodistally and incisal-apically. Preparation of the access cavity for the mandibular canine is oval or slot-shaped. The mesiodistal width corresponds to the mesiodistal width of the pulp chamber. The incisal extension can approach the incisal edge

of the tooth for straight-line access, and the gingival extension must penetrate the cingulum to allow a search for a possible lingual canal. As with the mandibular incisors, butt joint relationships between internal walls and the lingual surface are not necessary (Figure J).

Mandibular First Premolar

The chamber shape is usually oval or rounded, as is the access opening on the occlusal surface. As in many other circumstances, above, the access opening should be in the middle third of the tooth, both mesiodistally and buccolingually. Whenever possible, the buccal cusp should be preserved without being undermined during access opening preparation. The oval external outline form of the mandibular first premolar is typically wider mesiodistally than its maxillary counterpart, making it more oval and less slot-shaped. Because of the lingual inclination of the crown, buccal extension can nearly approach the tip of the buccal cusp to achieve straight-line access. Lingual extension barely invades the poorly developed lingual cusp incline. Mesiodistally, the access preparation is centered between the cusp tips. Often the preparation must be modified to allow access to the complex root canal anatomy frequently seen in the apical half of the tooth root (Figure K).

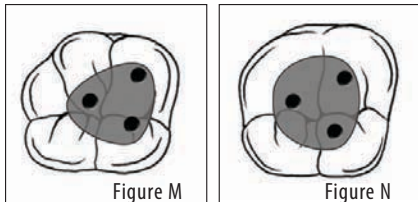
Mandibular Second Premolar

As with the mandibular first premolar, the chamber morphology is usually oval or rounded, as is the access opening on the occlusal surface. Additionally, the access opening should be in the middle third of the tooth, both mesiodistally and buccolingually, and the buccal and lingual cusps should not be undermined during access opening prepara-

tion. There are at least two variations in the external anatomy that affect the access cavity form of the mandibular second premolar. First, because the crown typically has a smaller lingual inclination, less extension up the buccal cusp incline is required to achieve straight-line access. Second, the lingual half of the tooth is more fully developed. Consequently, the lingual access extension is typically halfway up the lingual cusp incline. The mandibular second premolar can have two lingual cusps, sometimes of equal size. When this occurs, the access preparation is centered mesiodistally on a line connecting the buccal cusp and the lingual groove between the lingual cusp tips. When the mesiolingual cusp is larger than the distolingual cusp, the lingual extension of the oval outline form is just distal to the tip of the mesiolingual cusp (Figure L).

Mandibular First Molar

The chamber is usually triangular to square in shape. The access opening is triangular to slightly square on the occlusal surface, and its preparation should be distal to the mesial marginal ridge and primarily within the mesial half of the occlusal surface, keeping in mind that the distal extension of the access opening should extend into the distal half of the tooth. The access cavity for the mandibular first molar is typically trapezoid or rhomboid regardless of the number of canals present. When four or more canals are present, the corners of the trapezoid or rhombus should correspond to the positions of the main orifices. Mesially, the access need not invade the marginal ridge. Distal extension must allow straight-line access to the distal canal(s). The buccal wall forms a straight connection between the MB



and DB orifices, and the lingual wall connects the ML and DL orifices without bowing (Figure M).

Mandibular Second Molar

The chamber morphology is usually triangular. The opening of the access is triangular, but tends to straighten in a mesiodistal direction if two separate orifices are not present in the mesial root. Preparation should be distal to the mesial marginal ridge and primarily within the mesial half of the occlusal surface, although the distal extension of the access opening should extend into the distal half of the tooth. When three canals are present, the access cavity is very similar to that for the mandibular first molar, although perhaps a bit more triangular and less rhomboid. The distal orifice is less often ribbon-shaped buccolingually; therefore, the buccal and lingual walls converge more aggressively distally to form a triangle. The second molar may have only two canals, one mesial and one distal, in which case the orifices are nearly equal in size and line up in the buccolingual center of the tooth. The access cavity for a two-canal second molar is rectangular, wide mesiodistally and narrow buccolingually. The access cavity for a single-canal mandibular second molar is oval and is lined up in the center of the occlusal surface (Figure N).

Mandibular Third Molar

The morphology of the chamber is usually less triangular and more oval than the mandibular second molar. The access opening is also triangular to oval, with a pulp chamber that tends to be very large and very deep. The anatomy of the mandibular third molar is very unpredictable, and the access cavity can take any of several

shapes. When three or more canals are present, a traditional rounded triangle or rhombus is typical. When two canals are present, a rectangle is used, and for single-canal molars, an oval. Significant ethnic variation can be seen in the incidence of C-shaped root canal systems. This anatomy is much more common in Asians than Caucasians. Investigators in Japan⁸ and China⁹ found a 31.5 percent incidence of C-shaped canals. Others found the occurrence of C-shaped canals in a Chinese population to be 23 percent in mandibular first molars and 31.5 percent in mandibular second molars. Another study found an incidence rate of 19.1 percent in Lebanese subjects,¹⁰ whereas a different investigation found that 32.7 percent of Koreans had a C-shaped canal morphology in mandibular second molars.¹¹ The access cavity for teeth with a C-shaped root canal system varies considerably and depends on the pulp morphology of the specific tooth. These teeth pose a considerable technical challenge; however, use of the DOM, sonic and ultrasonic instrumentation, and plasticized obturation techniques greatly increase the likelihood of a successful treatment.

Conclusion

Adequate access is essential for successful non-surgical endodontic treatment. A straight line to the canal system that ultimately leads to the apex may achieve optimal results when it is based on knowledge of the internal morphology and observance of the principles of cavity preparation.

References

1. Black GV. Operative dentistry. 7th ed. Vol II. Chicago: Medico-Dental Publishing; 1936.
2. Krasner P, Rankow HJ. Anatomy of the pulp chamber floor. *Journal of Endodontics (JOE)* 2004;30(1):5.
3. Deutsch AS, Musikant BL. Morphological measurements of anatomic landmarks in human maxillary and mandibular molar pulp chambers. *JOE* 2004;30:388-90.
4. Kobayashi C, Yoshioka T, Suda H. A new engine-driven canal preparation system with electronic canal measuring

capability. *JOE* 1997;23:75.

5. Ingle JI, Bakland LK. Endodontics, 5th ed. Hamilton London; BC Decker, 2002:405.
6. Reeh ES, et al. Reduction in tooth stiffness as a result of endodontic and restorative procedures. *JOE* 1989;15:512.
7. Cohen S, Hargreaves KM. Pathways of the pulp, 9th ed. Elsevier; 2006:173.
8. Kotoku K. Morphological studies on the roots of the Japanese mandibular second molars. *Shikwa Gakuho* 1985;85:43.
9. Yang Z-P, Yang S-F, Lee G. The root and root canal anatomy of maxillary molars in a Chinese population. *Dent Traumatol* 1998;4:215.
10. Haddad GY, Nehma WB, Ounsi HF. Diagnosis, classification and frequency of C-shaped canals in mandibular second molars in the Lebanese population. *J Endodon* 1999;25:268.
11. Seo MS, Park DS. C-shaped root canals of mandibular second molars in a Korean population: clinical observation and in vitro analysis. *Int Endodon J* 2004;37(2):139.

Author Profile

All four of the authors are affiliated with the School of Dentistry at the University of Louisville in Louisville, Kentucky. Dr. R. Caicedo is a professor of Graduate Endodontics and director of the Junior Endodontics Course; Dr. S. Clark is a professor and director of the Graduate Endodontic Specialty Program; Dr. L. Roza is a professor in the Department of Diagnostic Sciences, Prosthodontics and Restorative Dentistry; and Mr. J. Fullmer is a fellow researcher and junior dental student.

Illustrations

All illustrations created by Briar Lee Mitchell

Disclaimer

The authors of this course have no commercial ties with the sponsors or the providers of the unrestricted educational grant for this course.

Reader Feedback

We encourage your comments on this or any PennWell course. For your convenience, an online feedback form is available at www.ineedce.com.

Questions

1. The most important phase of nonsurgical root canal treatment is:
 - a. Cavity preparation
 - b. Access
 - c. Pulp chambers
 - d. All of the above
2. When prepared correctly, the access cavity allows complete irrigation, shaping, cleaning, and quality of obturation.
 - a. True
 - b. False
3. The principles of cavity preparation should be applied while thinking of an endodontic preparation as a continuum from enamel surface to apex. These principles include:
 - a. Retention
 - b. Outline
 - c. Resistance forms
 - d. All of the above
4. Shape, size, and inclination must be correct in intracoronal preparation in order to:
 - a. Study the morphology of the chamber
 - b. Mentally visualize the third dimension
 - c. Accurately prepare and properly fill the radicular pulp space
 - d. Determine the location of pulp chambers and root canal orifices
5. The clinician must develop a two-dimensional visual in order to fully understand the anatomic concept of cavity preparation, as the endodontic cavity preparation and pulp anatomy are inseparable.
 - a. True
 - b. False
6. Endodontic preparations deal with both coronal and radicular access, each of which is achieved separately but ultimately flow together into a single preparation.
 - a. True
 - b. False
7. How must the endodontic cavity's outline form be shaped and positioned to correctly establish complete access for instrumentation?
 - a. Must have direct access to the apical foramen
 - b. Positioned from the cavosurface margin to apical foramen
 - c. Oval in shape
 - d. Access opening is triangular
8. The convenience form:
 - a. Provides a convenient and accurate preparation and filling of the root canal
 - b. Provides completes authority over the enlarging instrument
 - c. Modifies the cavity outline form to establish greater convenience in placement of intracoronal restorations
 - d. All of the above
9. Why must remaining carious dentin and defective restorations be removed?
 - a. To eliminate as many bacteria as possible from the interior tooth
 - b. To eliminate the discolored tooth structure that may ultimately lead to staining of the crown
 - c. Both of the above
 - d. None of the above
10. When cleansing the cavity, access preparation should include:
 - a. Removal of purulent fluids
 - b. Removal of hemorrhagic fluids
 - c. Flushing action of debris and dentin chips
 - d. All of the above
11. Due to the possibility of an air embolism, necrotic material must be removed from the chamber with an air syringe before the radicular instrumentation is begun.
 - a. True
 - b. False
12. The outline form of the access cavity for maxillary central incisors changes to a more oval shape as the tooth matures and the pulp horns recede.
 - a. True
 - b. False
13. In maxillary lateral incisors, the chamber is:
 - a. Triangular in shape
 - b. Proportionately larger in the middle third of the lingual surface of the tooth
 - c. Both of the above
 - d. None of the above
14. Due to the shape of the maxillary canine chamber:
 - a. The buccal and lingual cusps should not be undermined during access opening preparation.
 - b. The oval is usually centered between the mesial pit and the mesial edge of the oblique ridge.
 - c. The access opening must be filed labially and palatally to shape and clean the canal properly.
 - d. Preparation of the access should be distal to the mesial marginal ridge.
15. Due to the shape of the maxillary first premolar chamber:
 - a. The buccal and lingual cusps should not be undermined during access opening preparation.
 - b. The oval is usually centered between the mesial pit and the mesial edge of the oblique ridge.
 - c. The access opening must be filed labially and palatally to shape and clean the canal properly.
 - d. Preparation of the access should be distal to the mesial marginal ridge.
16. Due to the shape of the maxillary second premolar chamber:
 - a. The buccal and lingual cusps should not be undermined during access opening preparation.
 - b. The oval is usually centered between the mesial pit and the mesial edge of the oblique ridge.
 - c. The access opening must be filed labially and palatally to shape and clean the canal properly.
 - d. Preparation of the access should be distal to the mesial marginal ridge.
17. Due to the maxillary first molar chamber shape:
 - a. The buccal and lingual cusps should not be undermined during access opening preparation
 - b. The oval is usually centered between the mesial pit and the mesial edge of the oblique ridge
 - c. The access opening must be filed labially and palatally to shape and clean the canal properly
 - d. Preparation of the access should be distal to the mesial marginal ridge
18. The shape of the maxillary second molar chamber is usually more oval and less triangular than the maxillary first molar.
 - a. True
 - b. False
19. When four canals are present, the access cavity preparation of the maxillary second molar:
 - a. Has an oval shape and is a smaller version of the access cavity for the maxillary first molar
 - b. Has an oval shape and is widest in the buccolingual dimension
 - c. Has a triangular shape that is centered between the mesial pit and the mesial edge of the oblique ridge
 - d. Has a rhomboid shape and is a smaller version of the access cavity for the maxillary first molar
20. The access cavity form of the third molar can vary greatly, because the tooth typically has _____, which would require the access preparation to be anything from an oval that is widest in the buccolingual dimension to a rounded triangle similar to that used for the maxillary second molar.
 - a. One to two canals
 - b. One to three canals
 - c. Two to three canals
 - d. Two to four canals
21. Visualization of the canal orifice and straight-line access of the canal system for mandibular central and lateral incisors are restricted due to the presence of:
 - a. High pulp horns on distal aspects of chamber
 - b. High pulp horns on mesial aspects of chamber
 - c. A lingual ledge
 - d. None of the above
22. With mandibular central and lateral incisors, complete removal of the lingual shoulder is inconsequential, because this tooth often has two canals that are buccolingually oriented, and the lingual canal is often missed.
 - a. True
 - b. False
23. For the mandibular canine, the access opening:
 - a. Should be in the middle third of the tooth, both mesiodistally and buccolingually
 - b. Should be in the middle third of the tooth, both mesiodistally and incisal-apically
 - c. Is usually oval or rounded
 - d. None of the above
24. For the mandibular first premolar, the access opening:
 - a. Should be in the middle third of the tooth, both mesiodistally and buccolingually
 - b. Should be in the middle third of the tooth, both mesiodistally and incisal-apically
 - c. Is usually oval or rounded
 - d. None of the above
25. For the mandibular second premolar, the access opening:
 - a. Should be in the middle third of the tooth, both mesiodistally and buccolingually
 - b. Should be in the middle third of the tooth, both mesiodistally and incisal-apically
 - c. Is usually oval or rounded
 - d. None of the above
26. The access cavity form of the mandibular second premolar is affected by which variation in the external anatomy:
 - a. Smaller lingual inclination of the crown
 - b. More fully developed lingual half of the tooth
 - c. Both of the above
 - d. None of the above
27. For the mandibular first molar, the access opening may be slightly square, and its preparation should be distal to the mesial marginal ridge and primarily within the mesial half of the occlusal surface.
 - a. True
 - b. False
28. The distal orifice of the mandibular second molar is less often ribbon-shaped buccolingually; therefore:
 - a. The buccal and lingual walls converge more aggressively distally to form a triangle.
 - b. The buccal and lingual walls converge more aggressively mesiodistally to form a rhomboid.
 - c. The buccal and lingual walls converge more aggressively mesiodistally to form a triangle.
 - d. The two canals, one mesial and one distal, line up in the buccolingual center of the tooth.
29. Investigators in Japan and China found a _____ incidence of C-shaped root canal systems.
 - a. 19.1 percent
 - b. 23 percent
 - c. 31.5 percent
 - d. 32.7 percent
30. A straight line to the canal system that ultimately leads to the apex may achieve optimal results when it is based on knowledge of the internal morphology and observance of the principles of cavity preparation.
 - a. True
 - b. False

Guidelines for Access Cavity Preparation in Endodontics

Name: _____ Title: _____ Specialty: _____

Address: _____ E-mail: _____

City: _____ State: _____ ZIP: _____

Telephone: Home () _____ Office () _____

Requirements for successful completion of the course and to obtain dental continuing education credits: 1) Read the entire course. 2) Complete all information above. 3) Complete answer sheets in either pen or pencil. 4) Mark only one answer for each question. 5) A score of 70% on this test will earn you 4 CE credits. 6) Complete the Course Evaluation below. 7) Make check payable to PennWell Corp.

Educational Objectives

- Understand access as the most important phase of nonsurgical root canal treatment
- Comprehend principles of cavity preparation and proposed guidelines to accurately prepare and fill the radicular pulp space
- Understand the four parts to endodontic coronal cavity preparation—outline form, convenience form, removal of remaining carious dentin and defective restorations, and cleansing of the cavity
- Understand the differences in chamber and access shape for each tooth type and protocol to follow when performing on each

Course Evaluation

Please evaluate this course by responding to the following statements, using a scale of Excellent = 5 to Poor = 0.

1. Were the individual course objectives met?	Objective #1: Yes No	Objective #3: Yes No
	Objective #2: Yes No	Objective #4: Yes No
2. To what extent were the course objectives accomplished overall?	5 4 3 2 1 0	
3. Please rate your personal mastery of the course objectives.	5 4 3 2 1 0	
4. How would you rate the objectives and educational methods?	5 4 3 2 1 0	
5. How do you rate the author's grasp of the topic?	5 4 3 2 1 0	
6. Please rate the instructor's effectiveness.	5 4 3 2 1 0	
7. Was the overall administration of the course effective?	5 4 3 2 1 0	
8. Do you feel that the references were adequate?	Yes No	
9. Would you participate in a similar program on a different topic?	Yes No	
10. If any of the continuing education questions were unclear or ambiguous, please list them.		

11. Was there any subject matter you found confusing? Please describe.

12. What additional continuing dental education topics would you like to see?

Mail completed answer sheet to
Academy of Dental Therapeutics and Stomatology,
 A Division of PennWell Corp.
 P.O. Box 116, Chesterland, OH 44026
 or fax to: (440) 845-3447

For IMMEDIATE results, go to www.ineedce.com and click on the button "Take Tests Online." Answer sheets can be faxed with credit card payment to (440) 845-3447, (216) 398-7922, or (216) 255-6619.

Payment of \$59.00 is enclosed.
(Checks and credit cards are accepted.)

If paying by credit card, please complete the following: MC Visa AmEx Discover

Acct. Number: _____

Exp. Date: _____

Charges on your statement will show up as PennWell

- | | |
|---------------------|---------------------|
| 1. (A) (B) (C) (D) | 16. (A) (B) (C) (D) |
| 2. (A) (B) (C) (D) | 17. (A) (B) (C) (D) |
| 3. (A) (B) (C) (D) | 18. (A) (B) (C) (D) |
| 4. (A) (B) (C) (D) | 19. (A) (B) (C) (D) |
| 5. (A) (B) (C) (D) | 20. (A) (B) (C) (D) |
| 6. (A) (B) (C) (D) | 21. (A) (B) (C) (D) |
| 7. (A) (B) (C) (D) | 22. (A) (B) (C) (D) |
| 8. (A) (B) (C) (D) | 23. (A) (B) (C) (D) |
| 9. (A) (B) (C) (D) | 24. (A) (B) (C) (D) |
| 10. (A) (B) (C) (D) | 25. (A) (B) (C) (D) |
| 11. (A) (B) (C) (D) | 26. (A) (B) (C) (D) |
| 12. (A) (B) (C) (D) | 27. (A) (B) (C) (D) |
| 13. (A) (B) (C) (D) | 28. (A) (B) (C) (D) |
| 14. (A) (B) (C) (D) | 29. (A) (B) (C) (D) |
| 15. (A) (B) (C) (D) | 30. (A) (B) (C) (D) |

AGD Code 074

PLEASE PHOTOCOPY ANSWER SHEET FOR ADDITIONAL PARTICIPANTS.

AUTHOR DISCLAIMER
 The authors of this course have no commercial ties with the sponsors or the providers of the unrestricted educational grant for this course.

SPONSOR/PROVIDER
 This course was made possible through an unrestricted educational grant. No manufacturer or third party has had any input into the development of course content. All content has been derived from references listed, and/or the opinions of clinicians. Please direct all questions pertaining to PennWell or the administration of this course to Machele Galloway, 1421 S. Sheridan Rd., Tulsa, OK 74112 or macheleg@pennwell.com.

COURSE EVALUATION AND PARTICIPANT FEEDBACK
 We encourage participant feedback pertaining to all courses. Please be sure to complete the survey included with the course. Please e-mail all questions to: macheleg@pennwell.com.

INSTRUCTIONS
 All questions should have only one answer. Grading of this examination is done manually. Participants will receive confirmation of passing by receipt of a verification form. Verification forms will be mailed within two weeks after taking an examination.

EDUCATIONAL DISCLAIMER
 The opinions of efficacy or perceived value of any products or companies mentioned in this course and expressed herein are those of the author(s) of the course and do not necessarily reflect those of PennWell.

Completing a single continuing education course does not provide enough information to give the participant the feeling that s/he is an expert in the field related to the course topic. It is a combination of many educational courses and clinical experience that allows the participant to develop skills and expertise.

COURSE CREDITS/COST
 All participants scoring at least 70% (answering 21 or more questions correctly) on the examination will receive a verification form verifying 4 CE credits. The formal continuing education program of this sponsor is accepted by the AGD for Fellowship/Membership credit. Please contact PennWell for current term of acceptance. Participants are urged to contact their state dental boards for continuing education requirements. PennWell is a California Provider. The California Provider number is 3274. The cost for courses ranges from \$49.00 to \$110.00.

Many PennWell self-study courses have been approved by the Dental Assisting National Board, Inc. (DANB) and can be used by dental assistants who are DANB certified to meet DANB's annual continuing education requirements. To find out if this course or any other PennWell course has been approved by DANB, please contact DANB's Recertification Department at 1-800-FOR-DANB, ext. 445.

RECORD KEEPING
 PennWell maintains records of your successful completion of any exam. Please contact our offices for a copy of your continuing education credits report. This report, which will list all credits earned to date, will be generated and mailed to you within five business days of receipt.

CANCELLATION/REFUND POLICY
 Any participant who is not 100% satisfied with this course can request a full refund by contacting PennWell in writing.

© 2008 by the Academy of Dental Therapeutics and Stomatology, a division of PennWell